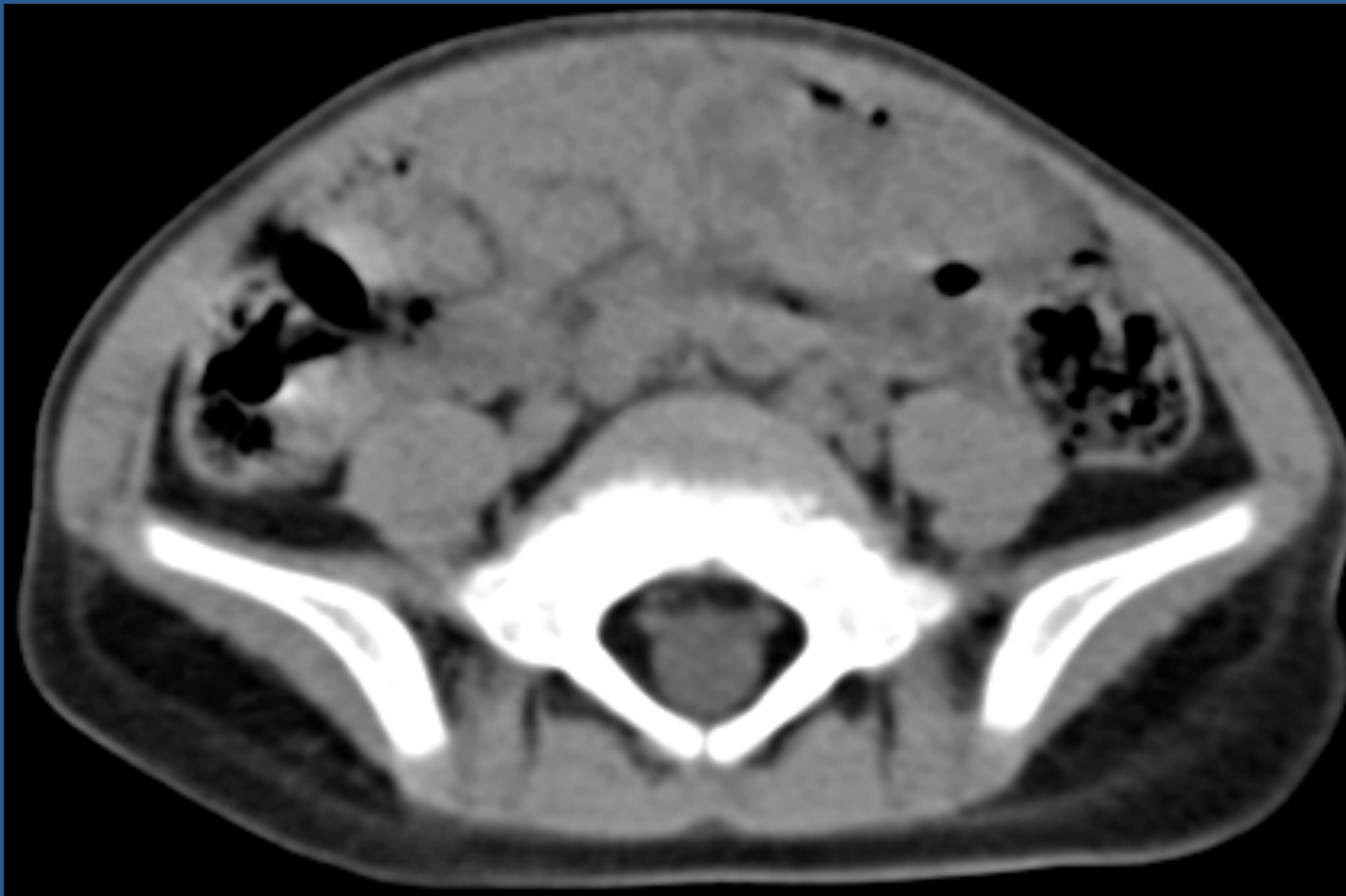


# レジデントレクチャー

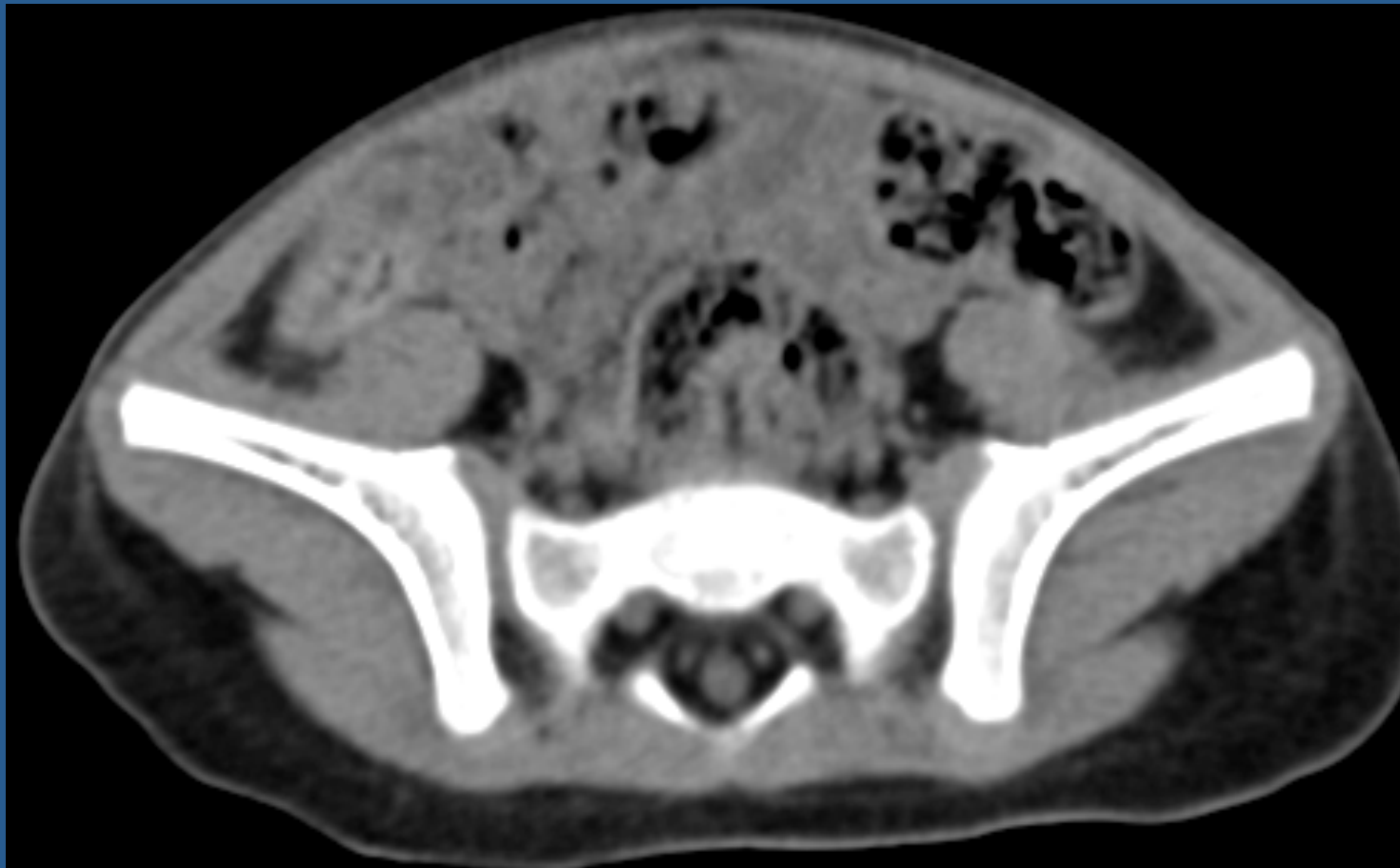
3歲 女

- 主訴 肝機能異常
- 既往 ？？

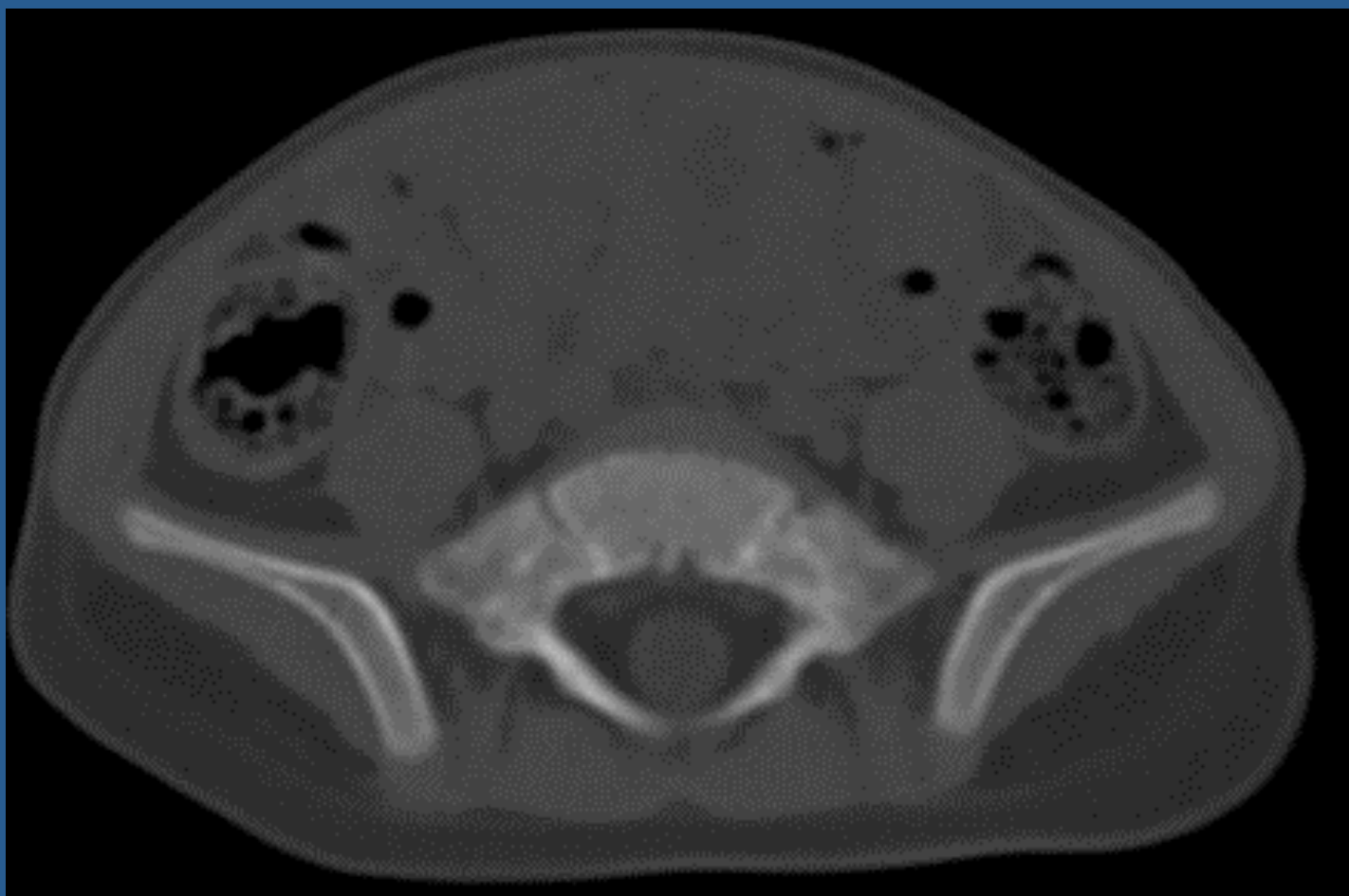
# 腹部CT 単純



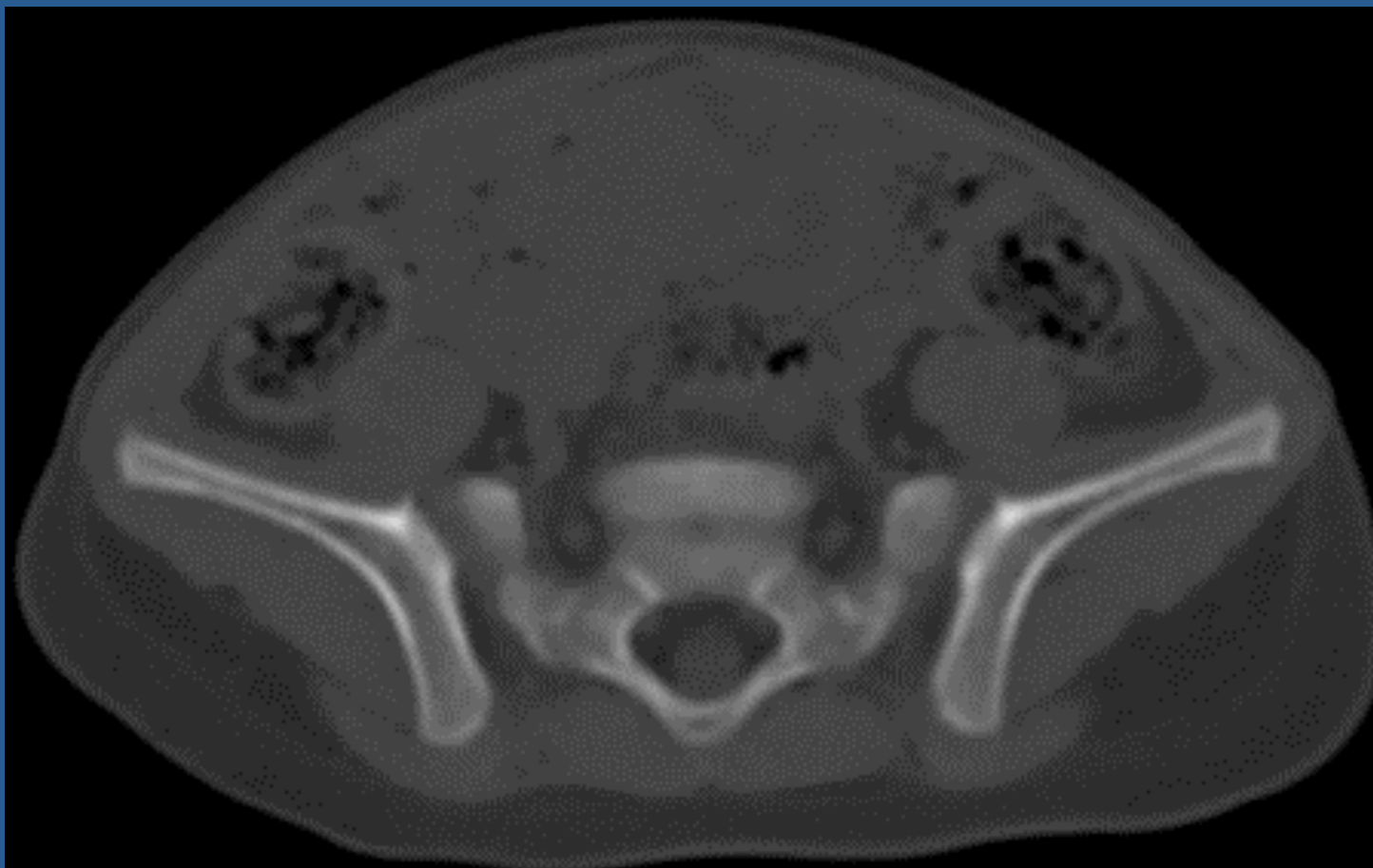
# 腹部CT 単純



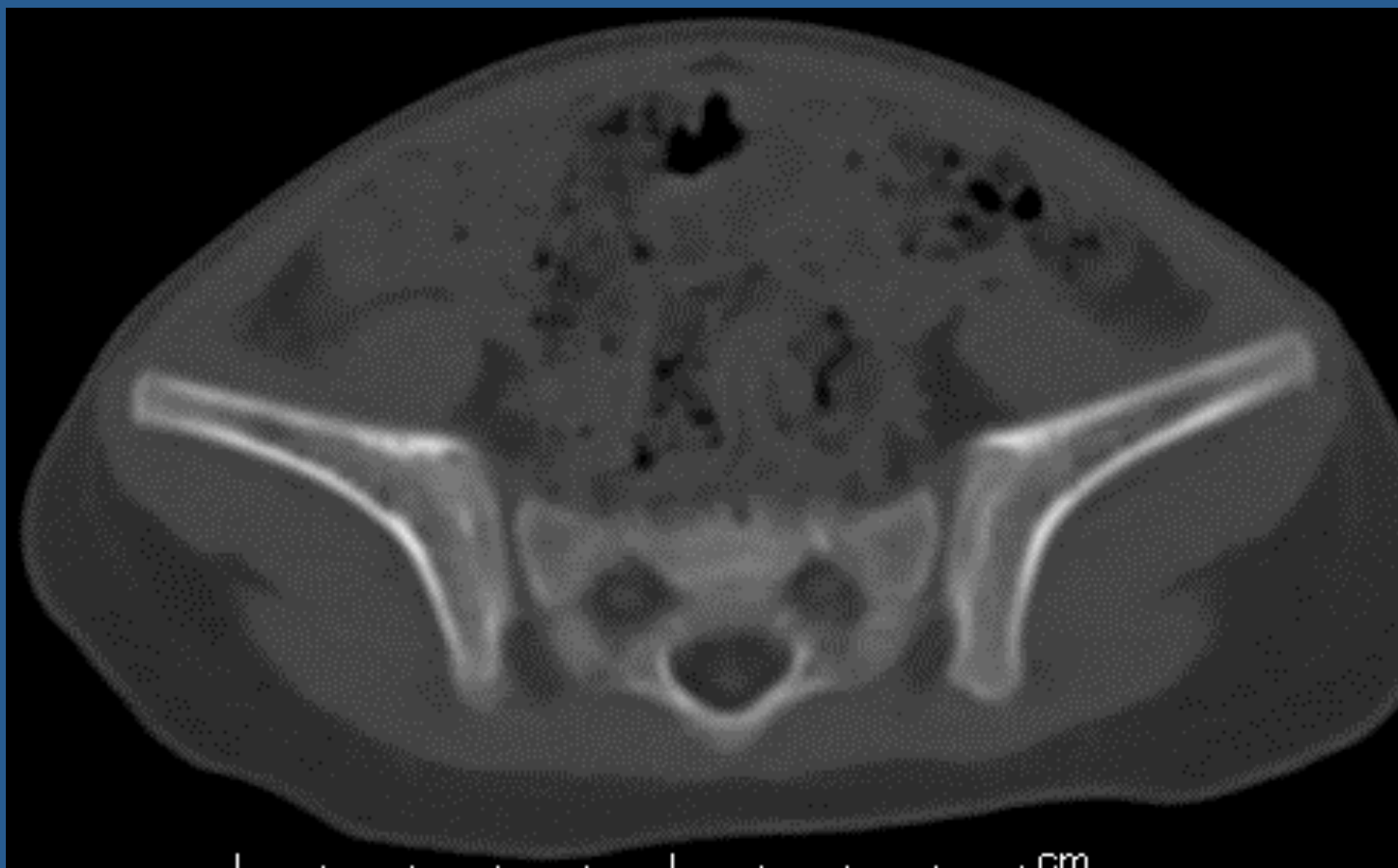
# 腹部CT 単純 骨条件



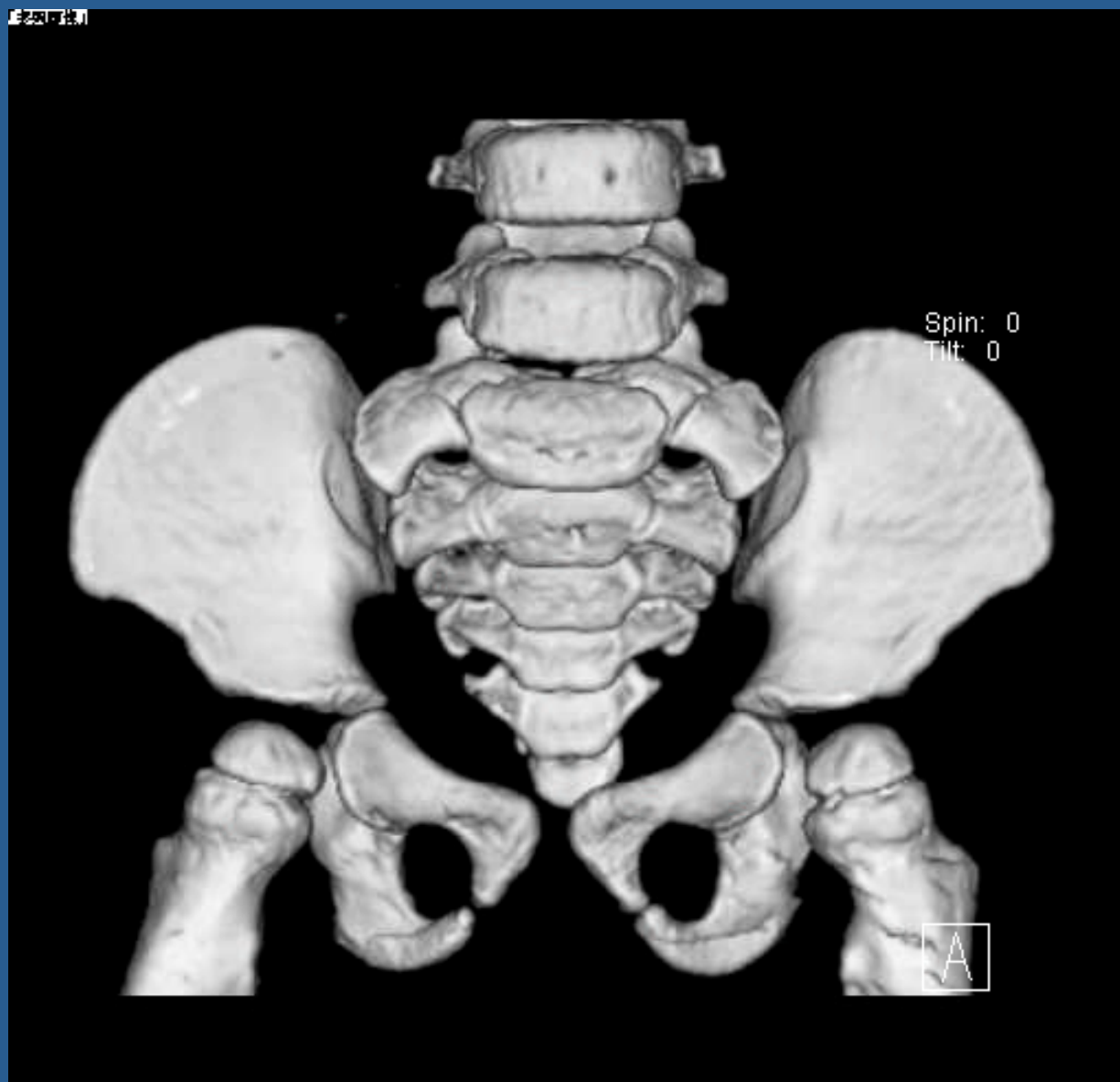# 腹部CT 単純 骨条件



# 腹部CT 単純 骨条件

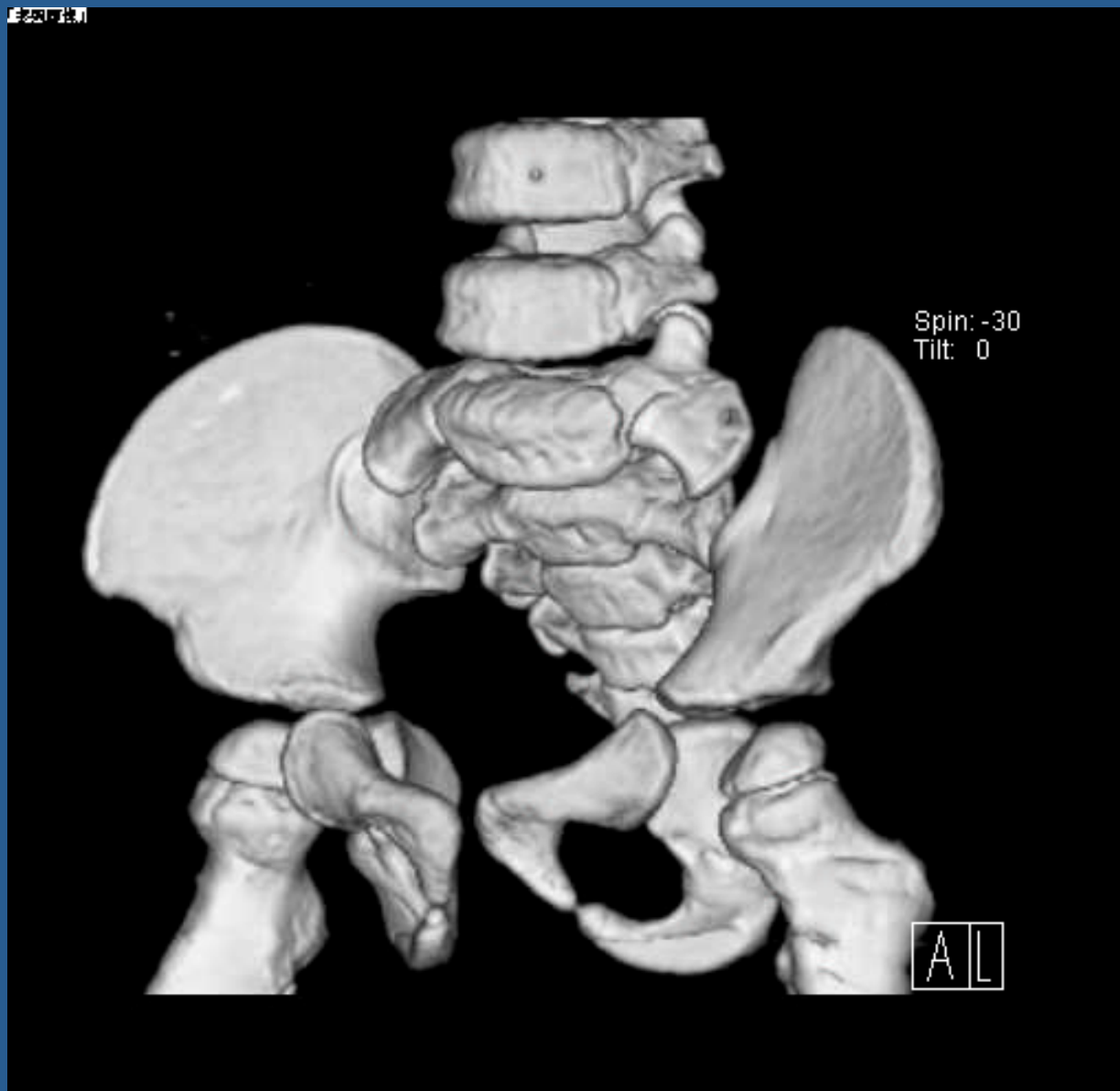

# 腹部CT 3D再構築





# 腹部CT 3D再構築



intermission

# 診断

ダウン症/21トリソミー

# ダウン症

- 21番染色体を3本持つ疾患群
- 特異的顔貌、知的障害、先天性心疾患、低身長、肥満、筋力の弱さ、頰椎の不安定性、眼科的問題(先天性白内障、眼振、斜視、屈折異常)、難聴

# Iliac angleの拡大

iliac index

腸骨の長さが短い

# Flared iliac wings

- Bladder exstrophy
- chromosome 21 trisomy (Down syndrome)
- osteo-onycho dysostosis  
(nail-patella syndrome)
- Rubinstein-Taybi syndrome
- sacral agenesis

Down症の80%にflared iliac wing

Radiology 2000; 214: 205-208.

Radiology 1998; 206:846-847

RadioGraphics 1992; 12: 467-484

# 胎児超音波

- thickened nuchal fold
- short long bones
- heart defects
- pyelectasis
- hyperechoic bowel
- Iliac angle拡大
- 腸骨の前部をつないだ径の延長

*AJR* 2001; 176:1003-1007

*J Ultrasound Med* 1990;9:389-3

# 鎖骨のConoid Process (烏口鎖骨靭帯付着部)

AJR 1993; 160: 591- 592